Royal College of Surgeons in Ireland
e-publications@RCSI

General Practice Articles

Department of General Practice

2-1-2011

Outcome of periacetabular osteotomy for the management of acetabular dysplasia: experience in an academic centre.

Neil GM Burke
Royal College of Surgeons in Ireland

Brian M. Devitt
Royal College of Surgeons in Ireland

Joseph F. Baker
Royal College of Surgeons in Ireland

Joseph S. Butler
Royal College of Surgeons in Ireland

Grainne Cousins
Royal College of Surgeons in Ireland, gcousins@rcsi.ie

See next page for additional authors

Citation

Burke NG, Devitt BM, Baker JF, Butler JS, Cousins G, McCormack D, O'Byrne JM. Outcome of periacetabular osteotomy for the management of acetabular dysplasia: experience in an academic centre. Acta Orthopaedic Belgica. 2011;77:33-40.

This Article is brought to you for free and open access by the Department of General Practice at e-publications@RCSI. It has been accepted for inclusion in General Practice Articles by an authorized administrator of e-publications@RCSI. For more information, please contact epubs@rcsi.ie.

Authors
Neil GM Burke, Brian M. Devitt, Joseph F. Baker, Joseph S. Butler, Grainne Cousins, Damian McCormack, and John M. O'Byrne

This article is available at e-publications@RCSI: http://epubs.rcsi.ie/gpart/8

— Use Licence —

Attribution-Non-Commercial-ShareAlike 1.0
You are free:
• to copy, distribute, display, and perform the work.
• to make derivative works.
Under the following conditions:
• Attribution — You must give the original author credit.
• Non-Commercial — You may not use this work for commercial purposes.
• Share Alike — If you alter, transform, or build upon this work, you may distribute the resulting work only under a licence identical to this one.
For any reuse or distribution, you must make clear to others the licence terms of this work. Any of these conditions can be waived if you get permission from the author.
Your fair use and other rights are in no way affected by the above.

This work is licenced under the Creative Commons Attribution-Non-Commercial-ShareAlike License. To view a copy of this licence, visit:
URL (human-readable summary):
• http://creativecommons.org/licenses/by-nc-sa/1.0/
URL (legal code):
• http://creativecommons.org/worldwide/uk/translated-license

This article is available at e-publications@RCSI: http://epubs.rcsi.ie/gpart/8

Acta Orthop. Belg., 2011, **77**, 33-40

ORIGINAL STUDY

Outcome of periacetabular osteotomy for the management of acetabular dysplasia : Experience in an academic centre

Neil G. Burke, Brian M. Devitt, Joseph F. Baker, Joseph S. Butler, Grainne Cousins, Damian McCormack, John M. O'Byrne

From Cappagh National Orthopaedic Hospital and Royal College of Surgeons in Ireland, Dublin, Ireland

Periacetabular osteotomy (PAO) is a very effective reconstructive procedure for treatment of acetabular dysplasia. An orthopaedic paediatric surgeon and a reconstructive hip arthroplasty surgeon performed this procedure together in the early phase of their learning curve and then performed it individually. The early clinical and radiographic results of 85 consecutive PAOs performed in this academic orthopaedic unit were reviewed.

The mean Merle-d'Aubigné score increased from 12.4 preoperatively to 16 at follow-up. Pre-operatively 73 hips were anteverted and 12 were neutral or retroverted. The mean angle of Wiberg improved from 5° to 21° ($p < 0.0001$) in anteverted hips, and from 9° to 30° in neutral or retroverted hips. The mean angle of Lequesne and de Sèze improved from 6° to 35° ($p < 0.0001$) in anteverted hips, and in neutral or retroverted hips from 9° to 30° ($p < 0.0001$). The acetabular index improved from 26° to 8° ($p < 0.0001$) in anteverted hips, and from 21° to 7° ($p < 0.0001$) in neutral or retroverted hips. Over the 7 year period the blood loss and operative time improved from 2000 ml to 900 ml and 4 hours to 2 hours respectively. Four hips (four patients) required conversion to total hip replacement.

The radiographic correction and improved clinical scores are similar to those in previous studies. This study shows a survival rate of 94% at 58 months following periacetabular osteotomy. The learning curve and the early results of this procedure performed in our academic unit are encouraging.

Keywords : acetabular dysplasia ; periacetabular osteotomy.

INTRODUCTION

Developmental dysplasia of the hip (DDH) is a common orthopaedic disorder. This condition is ideally diagnosed in infancy and may be treated effectively with a Pavlik harness or alternate abduction device. For the most part, this line of management is very successful with no later requirement for hip surgery. However, undiagnosed cases and those refractory to early conservative intervention

■ Neil G. Burke, MB BCh BAO, MRCSI, Orthopaedic Registrar.
■ Brian M. Devitt, MD, Orthopaedic Specialist Registrar.
■ Joseph F. Baker, MRCSEd, Orthopaedic Specialist Registrar.
■ Joseph S. Butler, MRCSI, Orthopaedic Specialist Registrar.
■ Damian McCormack, FRCS (Tr&Orth), Consultant Orthopaedic Surgeon, Professor.
■ John M. O'Byrne, FRCS (Tr&Orth), Consultant Orthopaedic Surgeon, Professor.
Department of Orthopaedic Surgery, Cappagh National Orthopaedic Hospital, Dublin, Ireland.
■ Grainne Cousins, PhD, Postdoctoral Researcher.
HRB Centre for Primary Care Research, Division of Population Health Science, Royal College of Surgeons in Ireland, Dublin, Ireland.
Correspondence : Mr Neil Burke, Department of Orthopaedic Surgery, Cappagh National Orthopaedic Hospital, Dublin, Ireland. E-mail : nei1burke@yahoo.co.uk
© 2011, Acta Orthopædica Belgica.

No benefits or funds were received in support of this study

can progress to severe acetabular dysplasia and this is the most common cause of secondary osteoarthrosis arising from pathological joint-loading forces (*4,8,13*). The inconsistent longevity of prosthetic joint replacement in younger patients, the presence of DDH bilaterally and non-acceptance of the limited role of arthrodesis has led orthopaedic surgeons to increasingly utilise joint preserving osteotomies in an attempt to obtain improved head coverage and enhanced joint congruity.

A number of reconstructive pelvic osteotomies for young adults with DDH and non-arthritic hips have been described in the literature (*1,4,17,18,20,21*). The Bernese periacetabular osteotomy (PAO) developed by Ganz *et al* in 1984 (*7*), has been shown to be an effective reconstructive option (*3,6,12,14,16, 19,20*). This procedure has a number of advantages over the other surgical options. Firstly, the series of straight reproducible cuts required can be performed through one incision. The posterior column of the hemipelvis remains intact, enabling immediate mobilization of the patient without the need for a cast or brace postoperatively. Multi-directional correction of the deficiency can be obtained by the appropriate orientation of the acetabulum and subsequent medialisation of the hip joint. The shape of the true pelvis is not altered significantly. The vascularity of the acetabular fragment is preserved as there is no dissection of the external aspect of the ischium and ilium and the vascular supply from the superior gluteal artery remains undisturbed. The labrum can also be examined without risk of additional devitalisation of the osteotomised fragment.

The success of this hip-preserving procedure is reflected in that it is now performed worldwide in many specialized institutions with consistent outcomes (*3,6,12,14,16,19,20*). The propagation of this surgical technique to the wider orthopaedic community, and the encouraging outcomes it offers patients, has led to increasing numbers of orthopaedic surgeons undertaking the complex procedure.

The purpose of this study was to examine the learning curve of the two senior authors performing this procedure, as one surgeon has a specialist interest in paediatric orthopaedics (DMC) and the other in reconstructive hip arthroplasty (JOB). We aimed to determine the complication rate, and the clinical and radiographic results of acetabular orientation pre-operatively and post-operatively of the Bernese periacetabular osteotomy performed by both surgeons over a 7 year period.

PATIENTS AND METHODS

Institutional review board approval was granted for this study. A retrospective review of the patients who had undergone a periacetabular osteotomy by the two senior authors (DMC, JOB) was performed. Between 1998 and 2005, 79 patients underwent 85 consecutive periacetabular osteotomies. Both surgeons assisted each other for the first 42 cases in the series, after which each performed the procedure individually. No concurrent procedures were carried out in addition to the PAO.

The two senior surgeons (DMC, JOB) were both fellowship trained in large academic orthopaedic centres in the United States. The fellowship of DMC involved extensive training in paediatric pelvic reconstructive osteotomies, in particular with the Bernese PAO. The senior author (JOB) received fellowship training in adult reconstructive hip surgery, but with limited exposure to paediatric hip surgery. Both senior authors then performed the periacetabular osteotomy on two cadavers for further refinement of technique.

Seventy-three hips had a radiological pre-operative diagnosis of acetabular dysplasia with anteversion, and 12 hips with acetabular dysplasia with a neutral or retroverted socket as shown in Table I. This was ascertained by the evaluation of the anteroposterior (AP) radiographs of the pelvis as regards the absence or presence of the 'cross-over sign' as described by Li and Ganz (*10*). Acetabular dysplasia associated with Legg-Calve-Perthes disease was diagnosed in one hip, with congenital coxa vara in three hips, and slipped capital femoral epiphysis in one hip.

Clinical evaluation using the validated Merle d'Aubigné-Postel hip score (*5*) was obtained pre-operatively and at post-operative follow-up at one year. Radiographic evaluation consisted of anteroposterior (AP) radiographs of the pelvis, and false profile views of the involved hip. These were obtained pre-operatively and then at 6 week, 6 month and at yearly periods post-operatively. Radiographic indices of dysplasia including the lateral center edge angle of Wiberg (*21*), the anterior center edge angle of Lequesne and de Sèze (*9*), the acetabular index angle of the loading zone (Tönnis) were documented (*18*). The radiographic measurements

Table I. — Acetabular Version

	Post-operative		
	Anteversion	Neutral	Retroversion
Pre-operative Orientation			
Anteversion (n = 73)	64 (87.7%)	5 (6.8%)	4 (5.4%)
Neutral (n = 2)	2 (100%)	0 (0%)	0 (0%)
Retroversion (n = 10)	8 (80%)	2 (20%)	0 (0%)
Post-operative Totals (n = 85)	74 (87.1%)	7 (8.2%)	4 (4.7%)

included the femoral head lateralization, and the integrity of Shenton's line on the AP radiograph. The Brooker grading was used to quantify the presence of heterotopic ossification (2).

Statistical analysis was carried out by using the Wilcoxon signed rank test to evaluate the difference between preoperative and postoperative clinical and radiological variables. Groups with different variables (e.g. preoperative osteoarthrosis) were compared using the Mann-Whitney U test. P-values of < 0.05 were considered significant. Kaplan-Meier survival analysis was performed using revision of the osteotomy or conversion to total hip arthroplasty as the end point.

Surgical Technique

The same operative technique was used by both surgeons and all osteotomies were performed under general anesthetic. The patient was positioned supine on a radiolucent table, and a modified Smith-Petersen approach was used. All patients underwent a periacetabular osteotomy under fluoroscopic guidance as described by Ganz *et al* (17).

It is important to confirm that the periacetabular segment is completely free and mobile. It is also necessary to identify, using imaging, that the fragment rotates over the head and does not merely hinge on a residual ischial attachment. The fragment can be placed provisionally in position and held with Kirschner wires. To confirm adequate correction and head cover, imaging in the AP and oblique planes is performed. The center edge angle is assessed along with Shenton's line and the position of the centre of the femoral head should be confirmed satisfactorily. The acetabular fragment should then be fixed with long 3.5 mm cortical screws. Imaging is undertaken to ensure the screws do not breach the articular surface.

A hip arthrotomy was performed if a labral tear was identified on a pre-operative MRI arthrogram or the patient had positive impingement pre-operatively. This involved either a osteochondroplasty or partial labral resection. Blood loss, length of time of surgery and intra-operative complications were recorded.

Postoperatively, patients had intravenous antibiotics for 24 hours and received thrombo-prophylaxis. The patient was mobilized one day postoperatively and kept partial weight bearing for six weeks. At six weeks, full weight bearing was commenced. All post-operative complications were documented.

RESULTS

Eighty-five PAOs were performed in 79 patients over a seven-year period (Figs. 1-4). The gender distribution was 72 women and 7 men. The mean age at time of procedure was 22.9 years (range 14-41 yrs). No patients had underlying neurological disorders or post-traumatic acetabular deficiency. Twenty-five previous surgical procedures were performed in 20 of the hips. The average operative time, defined as "skin-to-skin" time was 120 minutes (Fig. 5). The average estimated blood loss for all patients was 900 mL (Fig. 6). Seven patients underwent bilateral staged procedures. Forty-five periacetabular osteotomies were performed on the right hip and 40 on the left side. The senior authors assisted each other for the first 42 cases, and thereafter performed it alone. The mean follow-up in these patients was 59 months (range 16 to 96 months). No patients were lost to follow-up. Intra-operatively, no impingement was noted that would require a hip arthrotomy. The PAO was performed as the sole operation with no femoral osteotomies being carried out.

The mean Merle d'Aubigné-Postel hip score improved from 12.4 (range 9-14) preoperatively to

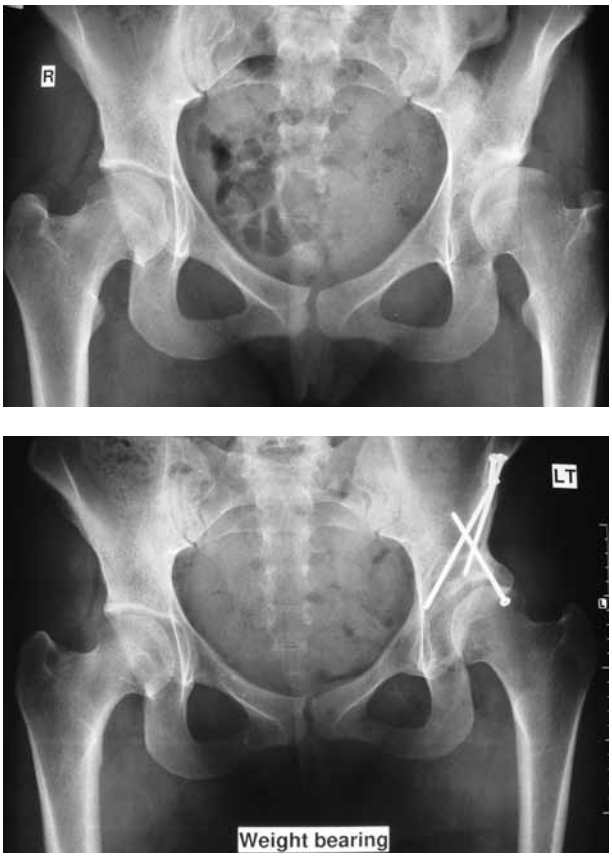

Figs. 1 & 2. — Pre-operative and three-years post-operative plain AP radiographs of the pelvis in an 18-year-old female. She underwent left PAO for DDH.

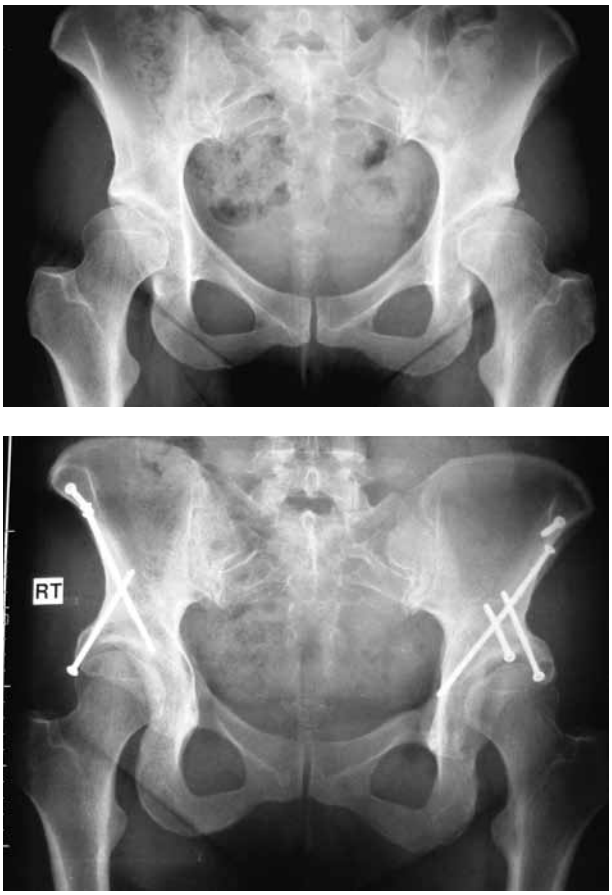

Figs. 3 & 4. — Pre-operative and six-years post-operative plain AP radiographs of the pelvic in an 38-year-old female. She underwent sequential PAO for bilateral DDH.

16 (range 11-18) postoperatively ($p < 0.0001$). The mean score for patients with an anteverted acetabulum pre-operatively improved from 10.4 (range 9-13) to 15 (12-18) at most recent follow-up ($p < 0.0001$). Those with a retroverted or neutral acetabulum improved from 11.5 (range 9-14) to 16.1 (range : 12-18) at most recent follow-up ($p < 0.0001$).

The average lateral center edge angle of Wiberg increased from 5° (range : -20° to 28°) preoperatively to 26° (range : -8° to 50°) postoperatively ($p < 0.0001$). The anterior center edge angle of Lequesne and de Sèze averaged 6° (range : - 22° to 35°) preoperatively and improved to 35° (range : -4° to 72°) postoperatively ($p < 0.0001$). The acetabular index angle decreased from an average of 24.8° (range : 4° to 46°) preoperatively to 8.4° (range : -22° to 42°) postoperatively ($p < 0.0001$). The radiographic findings are outlined in Table II. There was no significant difference in the acetabular wall orientation when the two senior surgeons operated together for the first 42 cases when compared to after when each consultant operated individually (DMC n = 24, JOB n = 19, $p > 0.05$).

Femoral head lateralization, which was quantified as the average distance from the most medial margin of the femoral head to the ischial line, decreased from 17 mm (range : 8.5-24 mm) preoperatively to 11 mm (range : 9.5-13.5 mm) postoperatively. The integrity of Shenton's line was broken in 59 hips preoperatively compared with 26 hips postoperatively. Eight hips had Brooker

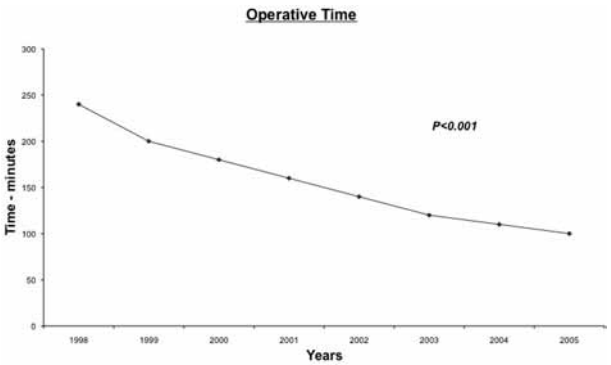

Fig. 5. — Plot displaying the total surgical time for the PAO with experience.

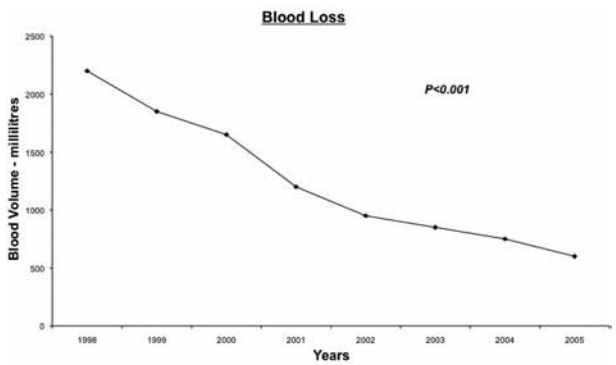

Fig. 6. — Plot showing the total estimated blood loss during surgery with experience.

Table II. — Radiographic Outcomes (all angles are in degrees)

Measurement	Pre-operative	Post-operative	Mean Correction	P Value
Pre-operative Anteversion				
Acetabular Index	26 (4 to 44)	8 (-22 to 42)	18	< 0.0001
Angle of Wiberg	5 (-26 to 28)	26 (8 to 52)	21	< 0.0001
Angle of Lequesne and de Sèze	6 (-22 to 35)	35 (-4 to 72)	29	< 0.0001
Pre-operative Retroversion or neutral				
Acetabular Index	21 (4 to 46)	7 (- 10 to 36)	14	< 0.0001
Angle of Wiberg	9 (-20 to 38)	30 (12 to 62)	21	< 0.0001
Angle of Lequesne and de Sèze	12 (2 to 35)	34 (6 to 70)	22	< 0.0001

Class I heterotopic ossification and one had Class II.

The degenerative changes according to Tönnis preoperatively were no arthritis in 33 hips, Grade I in 43 hips, and Grade II in 9 hips. At latest follow-up, no degenerative changes were found in 34 hips, Grade I in 40 hips, and Grade II in 7 hips. There was no correlation of clinical improvement measure with pre-operative Tönnis score.

Sixty-one patients had no or mild pain at follow-up (63 hips or 74%). Forty-eight patients were unlimited in physical activity (52 hips or 61%) at follow-up evaluation.

Upon commencement of this procedure in 1998, the operative time was approximately four hours with an average blood loss of 2000 ml. This improved over the seven year period to an operative time of two hours and blood loss of 900 ml (Fig. 6).

There were two major complications in the series. One patient had a venous bleed intra-operatively, which was successfully controlled. No further surgical intervention was required and the patient made a full recovery following blood transfusion. There was one case of intra-articular extension, which was managed conservatively with extended protected weight bearing for three months, and at the time of follow-up evaluation no long term sequelae were noted.

Four total hip arthroplasties were performed subsequent to PAO, with two from the group of patients when the consultants operated together, and one each when operating individually. Three of these patients had Tönnis grade II osteoarthrosis prior to the initial PAO and subsequently progressed despite satisfactory radiological correction. Progressive clinical and radiological deterioration

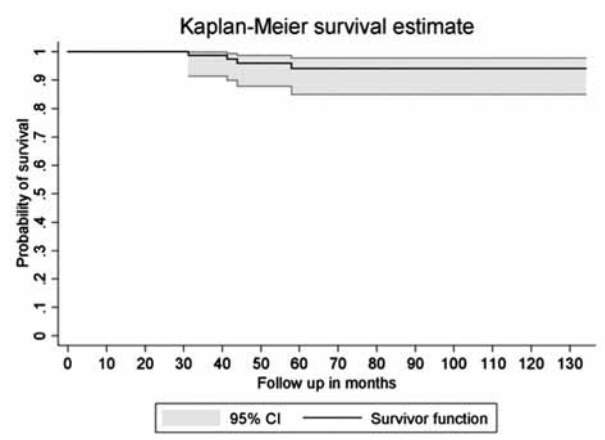

Fig. 7. — Kaplan-Meier survivorship curve for 83 hips, with revision periacetabular osteotomy or conversion to a total hip arthroplasty as the end point.

led to further intervention being warranted. The fourth patient requiring total hip arthroplasty developed an unrelated condition postoperatively, Churg Strauss Syndrome, necessitating treatment with high dose steroids. The patient later developed avascular necrosis of the femoral head on the affected side. The Kaplan-Meier survivorship at 58 months was 94% with the end point being conversion to total hip replacement as shown in Figure 7.

The presence of symptomatic hardware was observed in three individuals and removal of the irritant screws was performed in these instances. One patient was found to have a broken screw on routine follow-up, remained asymptomatic and the screw was left *in situ* without any subsequent adverse effects.

One patient required surgical debridement of the wound. A postoperative haematoma was evacuated in one hip. Thirteen patients (15%) developed transient lateral femoral cutaneous nerve dysfunction postoperatively, all had resolved by six-month follow-up.

DISCUSSION

The periacetabular osteotomy has been established as a safe and effective procedure for treating acetabular dysplasia with excellent reported outcomes in established acetabular units (*3,6,7,12,14,16, 19,20*). The operation seeks to provide "a biological solution for the mechanical problem" that exists in a dysplastic hip. The main objective of this procedure is to improve joint congruency and increase the area of contact at the articular surface, thereby decreasing the overall articular pressure. This has been shown to arrest the process of joint destruction and, in some cases, reverse it (*1,11*). It has also been demonstrated that proper execution of the procedure, individualized to correct the specific deficiency, may result in periarticular bone regeneration and apparent joint space preservation (*20*). In practical terms, the enhanced biomechanical function of the hip joint, translates into superior radiographic and functional outcome.

This series reports on the initial experience of two orthopaedic surgeons (DMC, JOB) with specialty interests in paediatric orthopaedic surgery and reconstructive hip arthroplasty respectively. Our results indicate the expected outcome in a unit that has specialized but not exclusive experience in this procedure.

In this study, we retrospectively reviewed 85 PAOs performed in 79 patients with a mean follow-up of 36 months. The patients in this series presented with varying conditions, however the majority of surgeries (n = 80) were performed for classical hip dysplasia. The severity of dysplasia ranged from deficits of anterior acetabular coverage with a stable femoral head to complete loss of the superior acetabular roof and chronic subluxation of the hip.

The extent of acetabular correction we achieved by this procedure was assessed by comparing preoperative and postoperative radiographs. The success of this procedure, however, is not simply determined on the level of acetabular reorientation, but also on the clinical and functional improvement experienced by the patient. Our data reported correlates satisfactorily with other studies in the literature (*3,6,12,14,16,19,20*).

Performing new procedures is associated with a learning curve. Operative time and blood loss, in general, reflect the proficiency of the individual performing the operation. As shown, over the seven-year period the operating time reduced by half and blood loss by more than half. The majority

of complications in our study occurred during the early part of the learning curve with this osteotomy. Most were considered minor and representative of an acceptable risk for an initial consecutive series of 85 operations. It has been reported that the complication rates associated with this procedure diminish over time as the surgeon becomes more experienced and adept at the procedure (*6*). Thus, we are confident that in the population of patients with acetabular dysplasia presenting to our service, our complication rate will continue to decrease as our experience increases.

The presence of two consultants at the initial series of operations was advantageous with respect to overcoming initial difficulties with orientation and selection of osteotomy positions. This also provided the opportunity for collaboration and discussion on how to improve technique and create a preoperative plan for difficult cases. It has been noted previously that correct acetabular orientation is challenging – too much correction in one direction can lead to impingement – and this comprises a significant portion of the initial learning curve. Ganz *et al* and Peters *et al* identified a learning curve of 20 to 30 hips, and this is reinforced by the learning curve of the two senior authors in this study (*7,15*).

In summary, this study reports on acetabular correction, complications, and early clinical and functional performance in our academic institution. The results show it is being performed safely and with effective outcomes, as these compare favorably with other institutions performing the periacetabular osteotomy (*3,6,12,14,16,19,20*). Although this is a challenging procedure, the learning curve of these two consultant orthopaedic surgeons show that the initial surgical experience can be enhanced by collaboration with other interested or experienced colleagues, producing overall satisfactory results.

REFERENCES

1. **Bombelli R, Aronson J.** Biomechanical Classification of Osteoarthritis of the Hip with Special Reference to Treatment Techniques and Results. In : Schatker J, ed. *The Intertrochanteric Osteotomy*. Springer-Verlag, Berlin, 1984, pp 67-134.
2. **Brooker AF, Bowerman JW, Robinson RA, Riley LH Jr.** Ectopic ossification following total hip replacement. Incidence and a method of classification. *J Bone Joint Surg* 1973 ; 55-A : 1629-1632.
3. **Clohisy JC, Barrett SE, Gordon JE, Delgado ED, Schoenecker PL.** Periacetabular osteotomy for the treatment of severe acetabular dysplasia. *J Bone Joint Surg* 2005 ; 87-A : 254-259.
4. **Cooperman DR, Wallensten R, Stulberg SD.** Postreduction avascular necrosis in congenital dislocation of the hip. *J Bone Joint Surg* 1980 ; 62-A : 247-258.
5. **d'Aubigné RM, Postel M.** Function al results of hip arthroplasty with acrylic prosthesis. *J Bone Joint Surg* 1954 ; 36-A : 451-475.
6. **Davey JP, Santore RF.** Complications of periacetabular osteotomy. *Clin Orthop Relat Res* 1999 ; 363 : 33-37.
7. **Ganz R, Klaue K, Vinh TS, Mast JW.** A new periacetabular osteotomy for the treatment of hip dysplasias. Technique and preliminary results. *Clin Orthop Relat Res* 1988 ; 232 : 26-36.
8. **Ito K, Minka MA, 2nd, Leunig M, Werlen S, Ganz R.** Femoroacetabular impingement and the cam-effect. A MRI-based quantitative anatomical study of the femoral head-neck offset. *J Bone Joint Surg* 2001 ; 83-B : 171-176.
9. **Lequesne M, de Sèze S.** [False profile of the pelvis. A new radiographic incidence for the study of the hip. Its use in dysplasias and different coxopathies.] (in French). *Rev Rhum Mal Ostéoartic* 1961 ; 28 : 643-652.
10. **Li PL, Ganz R.** Morphologic features of congenital acetabular dysplasia : one in six is retroverted. *Clin Orthop Relat Res* 2003 ; 416 : 245-253.
11. **Maquet P.** Dysplastic Hips. In : PGJ M, ed. *Biomechanics of the Hip. As Applied To Osteoarthritis and Related Conditions*. Springer-Verlag, Berlin : 1985 : pp 253-282.
12. **Matta JM, Stover MD, Siebenrock K.** Periacetabular osteotomy through the Smith-Petersen approach. *Clin Orthop Relat Res* 1999 ; 363 : 21-32.
13. **Millis MB, Murphy SB, Poss R.** Osteotomies about the hip for the prevention and treatment of osteoarthrosis. *Instr Course Lect* 1996 ; 45 : 209-226.
14. **Murphy SB, Millis MB.** Periacetabular osteotomy without abductor dissection using direct anterior exposure. *Clin Orthop Relat Res* 1999 ; 364 : 92-98.
15. **Peters CL, Erickson JA, Hines JL.** Early results of the Bernese periacetabular osteotomy : the learning curve at an academic medical center. *J Bone Joint Surg* 2006 ; 88-A : 1920-1926.
16. **Siebenrock KA, Scholl E, Lottenbach M, Ganz R.** Bernese periacetabular osteotomy. *Clin Orthop Relat Res* 1999 ; 363 : 9-20.
17. **Thawrani D, Sucato DJ, Podeszwa DA, DeLaRocha A.** Complications associated with the Bernese periacetabular osteotomy for hip dysplasia in adolescents. *J Bone Joint Surg* 2010 ; 92-A : 1707-1714.

18. **Tonnis D.** General Radiology of the Hip Joint. In : Tonnis D (ed). *Congenital Dysplasia and Dislocations of the Hip in Children and Adults*. Springer, Heidelberg : 1987 : pp 100-142.
19. **Trousdale RT, Ekkernkamp A, Ganz R, Wallrichs SL.** Periacetabular and intertrochanteric osteotomy for the treatment of osteoarthrosis in dysplastic hips. *J Bone Joint Surg* 1995 ; 77-A : 73-85.
20. **Trumble SJ, Mayo KA, Mast JW.** The periacetabular osteotomy. Minimum 2 year follow up in more than 100 hips. *Clin Orthop Relat Res* 1999 ; 363 : 54-63.
21. **Wiberg G.** Studies on dysplastic acetabula and congenital subluxation of the hip joint : with special reference to the complication of osteoarthritis. *Acta Chir Scand* 1939 ; 83(Suppl 58) : 40-138.